

N.M. Seidalieva^{1*}, N.A. Ibragimova², A.K. Saidakhmetova³,
B.A. Ussipbek¹, D.B. Mirzalieva¹, S.M. Shalgimbayeva¹

¹Al-Farabi Kazakh National University, Almaty, Kazakhstan

²Scientific Center of Anti-Infective Drugs, Almaty, Kazakhstan

³S.J. Asfendiyarov Kazakh National Medical University, Almaty, Kazakhstan

*e-mail: seidalieva_nagima@mail.ru

ASSESSMENT OF THE PHYSIOLOGICAL CONDITION OF YOUNG-OF-THE-YEAR CYPRINID FISH INFECTED WITH MYXOSPOREANS

The physiological condition of young-of-the-year mirror carp (*Cyprinus carpio*) reared under pond aquaculture conditions and infected with myxosporeans was investigated. The study aimed to assess the effects of myxosporean infection on the physiological and hematological parameters of cyprinid fishes. Infected individuals exhibited pronounced clinical signs of the disease, frequently accompanied by mortality. Hematological analysis revealed high levels of monocytes, neutrophils (32.68%), and white blood cells ($257.6 \times 10^9/L$) compared to the norm. Elevated differential leukocyte counts indicate an increased defense reaction of the organism under conditions of parasitic invasion. Histological examination of gills, heart, intestine, hepatopancreas and musculature revealed the presence of intracellular, interstitial, and diffuse localization of parasitic mucous spores (*Myxozoa: Myxosporea: Myxobolidea*). Necrosis, desquamation, hyperplasia and a dramatic increase of mast cells in the gills of the studied fish are due to both small intracellular plasmodia and spores located inside tissue cysts. The increase in the number of mast cells in the gills of fish in localization of mucous parasites is associated with the need to maintain homeostasis of the immune system. The pathological effect of myxosporean plasmodia on organs of the digestive tract were established, causing necrosis, disruption of cell absorption and transport processes, as well as reduction of the height of prismatic epithelial cells with degeneration of microvilli on their apical surface. Intracellular parasitism of uninucleate and binucleate mucous myxosporeans were also observed in the cells of the hepatopancreas and heart. Necrotic foci located on the skin of the fish were a manifestation of the inflammatory process and hemorrhages in the muscles due to parasitic invasion.

Keywords: fish farming, cyprinid fish, hematology, histology, gills, hepatopancreas, heart.

Н.М. Сейдалиева^{1*}, Н.А. Ибрагимова², А.К. Сайдахметова³,
Б.А. Үсіпбек¹, Д.Б. Мирзалиева¹, С.М. Шалгимбаева¹

¹Әл-Фараби атындағы Қазақ ұлттық университеті, Алматы, Қазақстан

²Инфекцияға қарсы препараттар ғылыми орталығы, Алматы, Қазақстан

³С.Ж. Асфендияров атындағы Қазақ ұлттық медициналық университеті, Алматы, Қазақстан

*e-mail: seidalieva_nagima@mail.ru

Микоспоридиямен инвазияланған жас тұқы балықтарының физиологиялық жағдайларын бағалау

Мақалада тоған аквашаруашылығы жағдайында өсірілетін және микоспоридиялық инвазиямен зақымданған жас айна тұқы балығының (*Cyprinus carpio*) физиологиялық жағдайы қарастырылады. Жұмыстың мақсаты тұқы балықтарының физиологиялық және гематологиялық көрсеткіштеріне микоспоридиялармен паразиттік зақымданудың әсерін бағалау болып табылады. Жұқтырылған дараларда көбінесе балықтардың өлімімен бірге жүретін аурудың клиникалық белгілері байқалды. Гематологиялық тексеру кезінде моноциттердің, нейтрофилдердің (32,68%) және лейкоциттердің ($257,6 \times 10^9/L$) қалыпты көрсеткішпен салыстырғанда жоғары мөлшері анықталды. Паразиттік инвазия жағдайында лейкоциттік формула көрсеткіштерінің жоғарлауы организмнің қорғаныш реакциясының артқанын көрсетеді. Желбезектердің, жүректің, ішектің, гепатопанкреастың және бұлшықеттердің гистологиялық зерттеу нәтижесі паразиттік шырышты спораларының (*Myxozoa: Myxosporea: Myxobolidea*) жасушаішілік, ұлпаішілік және шашырап орналасатыны анықталды. Зерттелген балықтардың желбезектеріндегі некроз, қабыршақтану, гиперплазия және мес жасушаның күрт көбеюі ұсақ жасушаішілік плазмодиялармен де, тіндік цисталардың ішінде орналасқан споралармен де байланысты. Балықтардың желбезектеріндегі шырышты паразиттер орналасқан жерлерде мес жасуша санының артуы иммундық жүйенің

гомеостазын сақтау қажеттілігімен байланысты. Миксоспоридий плазмодиялары некрозға, жасушалардың сіңірілу және тасымалдану процестерінің бұзылуына, сондай-ақ призмалық эпителий жасушаларының биіктігінің төмендеуіне және олардың апикальді бетіндегі микробүрлердің дегенерациясына әкелетін ас қорыту жолдарының мүшелеріне патологиялық әсері анықталды. Бір және екі ядролы шырышты споралардың жасушаішілік паразиттелуі гепатопанкреас пен жүректің жасушаларында да байқалады. Балықтардың терісінде орналасқан некротикалық ошақтар паразиттік инвазияға байланысты қабыну процесінің және бұлшықетке қан кетудің көрінісі болды.

Түйін сөздер: балық өсіру шаруашылығы, тұқы балықтары, гематология, гистология, желбезектер, гепатопанкреас, жүрек.

Н.М. Сейдалиева^{1*}, Н.А. Ибрагимова², А.К. Сайдахметова³,
Б.А. Усипбек¹, Д.Б. Мирзалиева¹, С.М. Шалгимбаева¹

¹Казахский национальный университет им. аль-Фараби, Алматы, Казахстан

²Научный центр противоионфекционных препаратов, Алматы, Казахстан

³Казахский национальный медицинский университет им. С.Ж. Асфендиярова, Алматы, Казахстан

*e-mail: seidalieva_nagima@mail.ru

Оценка физиологического состояния сеголетков карповых рыб, инвазированных миксоспоридиями

В статье исследовано физиологическое состояние сеголетков зеркального карпа (*Cyprinus carpio*), выращиваемых в условиях прудовой аквакультуры и поражённых миксоспоридийной инвазией. Целью работы являлась оценка влияния паразитарного заражения миксоспоридиями на физиологические и гематологические показатели карповых рыб. У инфицированных особей отмечались клинические признаки заболевания, нередко сопровождавшиеся гибелью рыбы. При гематологическом исследовании было выявлено высокое содержание моноцитов, нейтрофилов (32,68%) и лейкоцитов ($257,6 \times 10^9/\lambda$) по сравнению с нормой. Повышенные показатели лейкоцитарной формулы свидетельствуют об усилении защитной реакции организма в условиях паразитарной инвазии. Гистологическое исследование жабр, сердца, кишечника, гепатопанкреаса и мускулатуры выявило наличие внутриклеточной, внутритканевой и диффузной локализации паразитических слизистых споровиков (*Myxozoa: Myxosporae: Myxobolidae*). Некроз, десквамация, гиперплазия и резкое увеличение тучных клеток в жабрах исследованных рыб обусловлены как мелкими внутриклеточными плазмодиями, так и спорами, расположенными внутри тканевых цист. Увеличение количества тучных клеток в жабрах рыб в местах локализации слизистых паразитов связано с необходимостью поддержания гомеостаза иммунной системы. Установлено патологическое воздействие плазмодиев миксоспоридий на органы пищеварительного тракта, вызывающее некроз, нарушение процессов всасывания и транспорта клеток, а также уменьшение высоты призматических эпителиоцитов с дегенерацией микроворсинок на их апикальной поверхности. Внутриклеточное паразитирование одно- и двуядерных слизистых споровиков наблюдалось также в клетках гепатопанкреаса и сердца. Некротизированные очаги, расположенные на кожных покровах рыб, являлись проявлением воспалительного процесса и кровоизлияний в мускулатуру вследствие паразитарной инвазии.

Ключевые слова: рыбоводное хозяйство, карповые рыбы, гематология, гистология, жабры, гепатопанкреас, сердце.

Introduction

Artificial cultivation of carp in Kazakhstan is of considerable importance, as it contributes to meeting the growing demand for high-quality fish products (Badryzlova et al., 2014). There are viral, bacterial, fungal, and parasitic infections, which are classified according to their pathogens. Ecto – and endoparasitic infections of carp in pond aquaculture systems are characterized by high biodiversity, significant epizootiological relevance, and pose a serious threat to fish farming. Previous studies have reported the current state of parasite fauna in commercially im-

portant fish species inhabiting the Kapchagay Reservoir (Mitenev, 2000).

Fish diseases negatively affect survival and growth rates, reduce heterosis effects achieved through interline crosses, increase feed conversion ratios, and ultimately lead to decreased farm profitability. In addition, diseases associated with adverse environmental factors may directly or indirectly cause mass fish mortality.

Among parasitic agents, protozoans and myxosporeans (*Myxosporae*) are the most common multicellular parasites of fish. They possess complex life cycles involving vertebrate hosts (primarily

fish, less frequently amphibians, reptiles, birds, and mammals) and invertebrate hosts, such as aquatic annelids and bryozoans (Lom & Dykova, 2006; Hallett et al., 2005). Myxosporeans frequently infect carp, however, only a limited number of species are recognized as pathogenic to pond fish. In Europe, severe clinical signs of this disease and the associated significant losses of carp are rarely reported. However, in Japan and People's Republic of China, species (e.g., *Myxobolus artus*, *M. koi*, *Thelohanel- lus kitauei*) have been reported to cause severe clinical signs and high mortality in fish farms cultivating the Far Eastern Subspecies of common carp (*Cyprinus carpio haematopterus*).

A total of 2425 species of myxospores have been described, at least 900 of which are myxobolids; a significant number of species have been detected in fish hosts of the order *Cypriniformes* (Eiras et al., 2005; Eiras et al., 2014; Liu et al., 2019). For carp cultured in the regions of CEE and CCA, five species (*Myxobolus cyprini*, *Sphaerospora dykova*, *S. molnari*, *Thelohanel- lus nikolskii*, and *T. hovorkai*) of economic importance, infecting common carp, and one species (*M. pavlovskii*) parasitizes bighead and silver carp (Food and Agriculture Organization of the United Nations, 2017). In highly infected fish, body condition is reduced, hemoglobin in the blood decreases, and gonadal development is delayed (Bruno et al., 1997).

It has been suggested that myxosporean infections may contribute to reductions in both wild and cultured populations of freshwater and marine fish species (Kent et al., 2014).

According to published data, young-of-the-year mirror carp exhibit higher susceptibility to myxosporean invasion compared with adult fish. Some authors have suggested that young flounders become infected with myxosporean *G. stephani* at a very early age (3 weeks after hatching) (Lom & Dykova, 1992). At low levels of infestation by parasites, adaptive blood reactions develop that do not become pathological without increasing levels of infestation. As pathogen numbers continue to increase, a stress response typically develops, often accompanied by pathological changes characteristic of acute disease (Golovina, 2018; Davydov, 2006). Changes in the fish's blood count depend on the degree of pathogenicity of the pathogen and the level of invasion. The differential white blood cell count is the most stable and objective indicator of physiological state and energy level of metabolic processes (Serpunin, 2010). The differential white blood cell count of one-year old carp was determined accord-

ing to the classification of fish blood cells by N.T. Ivanova (Ivanova, 1983).

Neutrophils are active enzyme-forming cells with phagocytic functions, the proportion of which increases during inflammatory processes and various intoxications (Moiseenko, 2000). Thus, neutrophil can be seen as an adaptation mechanism that enhances the protective function of blood under the influence of a set of adverse factors (Peskova, 2004). An increase in the number of eosinophils in the blood of mirror carp (*Cyprinus carpio*) indicates a parasitic invasion by myxosporeans, while an increase in neutrophils and monocytes indicates a concurrent inflammatory process. Mucous spores (*Myxozoa*), entering the host organs, begin intracellular division; also division can occur in intercellular space (Lom & Dykova, 2006). The formed primary parent cell undergoes further mitotic division, giving rise to secondary daughter cells. Thus, the primary cell, containing secondary plasmodium cells, is located in the cells of the primary epithelium and in the cartilaginous tissue of the gills. Therefore, multiple mitotic divisions greatly increase the number of parasites, which damage host cell metabolism and tissues due to their compressive effect (Kent et al., 2001). This process, turning into a long-term or chronic form, subsequently provokes various disorders in the internal organs of fish (necrosis, dystrophy, etc.) (Mineev, 2011).

The histological method does not always allow a sufficiently accurate diagnosis of the disease. However, it provides insight into the depth of the pathological process at cellular and tissue levels, as well as the extent of its impact on the entire fish population. In this context, organs from apparently healthy fish may exhibit various stages of pathology, enabling the determination of the overall degree of population damage (Chernysheva, 2002; Moiseenko, 2009).

Our pathomorphological study identified the invasion of myxosporeans in the gills, heart, intestines, and trunk muscles of mirror carp from a fish farm. The parasites found are identified as *M. muelleri* according to the methodology of Donec & Schulman (Dugarov et al., 2011; Donec & Schulman, 1984). However, Donec and Schulman found quite a wide range of hosts, and the description of the place of infestation by myxosporean parasites influence was inaccurate.

The aim of our study was to investigate the of parasitic invasion of myxosporeans (*Myxobolidae*) on the physiological state of carp fish species (*Cypriniformes*) grown in aquaculture condition.

Materials and methods

The objects of the study were young-of-the-year mirror carp from ponds at a fish farm in southern Kazakhstan. The fish were kept in ponds at temperatures of +14–16 °C; pH values varied seasonally, ranging from 6.5 to 8.5. Stocking density was 75,000 individuals per hectare in spring, increasing up to 40 tons of commercial fish per hectare during wintering.

Feeding was carried out using sinking feeds from Polish producer Aller Aqua, Kazakh combined feed Aqua Alliance, and Russian BIFF at doses of 1–2% of body weight. After examining all fish from

the ponds, specimens exhibiting visible lesions on the outer coverings, fins, gill arches, and internal organs were selected. The fish were measured and weighed; sex and age were determined, and average values were calculated: length ranged from 15.5 to 27 cm, weight from 86 to 250 g. Samples from affected areas showed uneven coloration with foci of necrotic tissue. Microscopy slides were prepared from these samples at magnifications of 10× and 40× (Figure 1).

In this study, fresh tissue samples of mirror carp organs were examined. Sections stained with hematoxylin and eosin were prepared for histological analysis.

Figure 1

Young-of-the-year mirror carp with integumentary lesions caused by myxosporeans



Blood samples were collected in May 2025 from 10 pond-reared young-of-the-year mirror carp (*Cyprinus carpio*) by cardiac puncture into tubes containing EDTA as an anticoagulant. Hematological parameters were determined using standard methods commonly applied in fish hematology (Serpunin, 2005). Red blood cell (RBC) count and hemoglobin concentration (HGB) were measured in all samples (n = 10) using a Z5Vet hematology analyzer (Zybio Inc., China). The white blood cell (WBC) count and differential leukocyte count were determined using the classical morphological method based on stained blood smears. For each fish, three blood smears were prepared, air-dried, and stained according to the standard Romanowsky method. The mean value obtained from the three smears were used for subsequent analysis. Leukocytes were counted under light microscopy (Leica Microsystems), and WBC concentration was calculated indirectly. Iden-

tification of blood cell types (lymphocytes, neutrophils, monocytes, and eosinophils) was performed based on morphological criteria, including cell size, nuclear shape and structure, and cytoplasmic characteristics, following previously published descriptions Ivanova, Clauss et al. (Ivanova, 1983; Clauss et al., 2008). Reference values of hematological parameters for juvenile *Cyprinus carpio* have been previously established and reported by Witeska et al., including normal ranges for hemoglobin, red and white blood cell counts, and leukocyte differentials (Witeska et al., 2016).

Histological studies. All fish with signs of disease were examined pathologically, after which samples were selected for histological analysis. The collected internal organs tissues were fixed in 10% formalin. Further sample processing was carried out in accordance with generally accepted methods (Bancroft & Gamble 2008). The resulting prepara-

tions were examined under the XJP-146JBT trinocular microscope at magnification $\times 10$, $\times 20$, $\times 40$, and $\times 100$.

Statistical analysis. Differences between parameters in diseased young-of-the-year mirror carp and reference values were assessed using a one-sample t-test.

$$t = \frac{\bar{x} - \mu_0}{SD/\sqrt{n}} \quad (1)$$

Where x is the sample mean, μ_0 is the reference value, SD is the standard deviation, and $n = 10$ represents the number of independent fish. Values obtained from the three blood smears per fish were averaged prior to statistical analysis. Differences were considered statistically significant at $p \leq 0.05$.

In addition, a nonparametric analysis was performed using the Wilcoxon signed-rank test. For each parameter, individual differences were calculated using the following formula:

$$d_i = x_i - x_{ref} \quad (2)$$

Where x_i is the individual value of the parameter and x_{ref} is the corresponding reference value. The absolute values of the differences $|d_i|$ were ranked, after which the ranks were summed taking into account the sign of the deviation. The test statistic was defined as the minimum of the sums of positive and negative ranks:

$$W = \min (\Sigma R^+, \Sigma R^-) \quad (3)$$

Results and discussion

As a result of respiratory dysfunction, the hemoglobin level in infected young-of-the-year mirror carp decreased from 96.9 g/L to 78.57 g/L, while the red blood cell count declined from $1.66 \times 10^{12}/L$ to $0.72 \times 10^{12}/L$. When an invasion occurs, the fish respond by increasing the protective response, which is an increase in the number of white blood cells and neutrophils while reducing the number of lymphocytes (Table 1).

Table 1
Hematological parameters of young-of-the-year mirror carps from aquaculture

Parameters	Reference values for young-of-the-year carp	Diseased mirror carp (<i>Cyprinus carpio</i>)		
		Avr.±Sd	p (t-test)	p (Wilcoxon)
Hemoglobin concentration, g/L	96,9	78,57±1,56	0,003	0,018
Red blood cell count, $\times 10^{12}/L$	1,66	0,72±0,2	<0,0001	0,016
White blood cell count, $\times 10^9 /L$	55,17	257,6±3,36	<0,001	0,016
Leukogram, %				
Eosinophil %	2,0	1,97±0,42	0,97	0,063
Neutrophil %	15,6	32,68±1,23	0,011	0,016
Monocytes %	1,7	11,34±1,11	0,008	0,016
Lymphocytes %	77,4	53,17±2,59	0,011	0,016

There is an increase in the number of neutrophils and monocytes, indicating a concomitant inflammatory process and the presence of intoxication. An increase in blood eosinophil counts is also observed, indicating a parasitic infestation by myxosporeans in young-of-the-year mirror carp (*Cyprinus carpio*).

For most parameters, a pronounced unidirectional deviation from reference values was observed (the results of the t-test confirmed the statistical significance of the differences, except for eosinophils). When the nonparametric Wilcoxon signed-rank test

was applied, all studied parameters (except eosinophils) also showed consistent deviation from the reference values, indicating high biological significance of the observed changes.

At low levels of fish parasite infestation, adaptive changes in the blood profile occur at early stages. Under artificial cultivation conditions, reduced host reactivity and resistance lead to an increase in parasite burden and disease incidence. Histological analysis of the presented data revealed the following distribution.


Histological studies

Gills. The life cycle of myxosporeans begins with intracellular parasitism, which is clearly visible in histological preparations of the gills of young-of-the-year mirror carp. Myxosporean plasmodia, entering the gill tissue, penetrate the cells of the primary epithelium, filling the empty spaces between

host tissue elements with young plasmodia. Small parasitic plasmodia intermingle with various elements of the gill cells. The release of the intracellular plasmodia is accompanied by the destruction of the affected gill tissue, as observed in the histological preparation of the gills of young-of-the-year mirror carp (Figure 2).

Figure 2

Microphotograph of myxosporean infected gills of a young-of-the-year mirror carp.

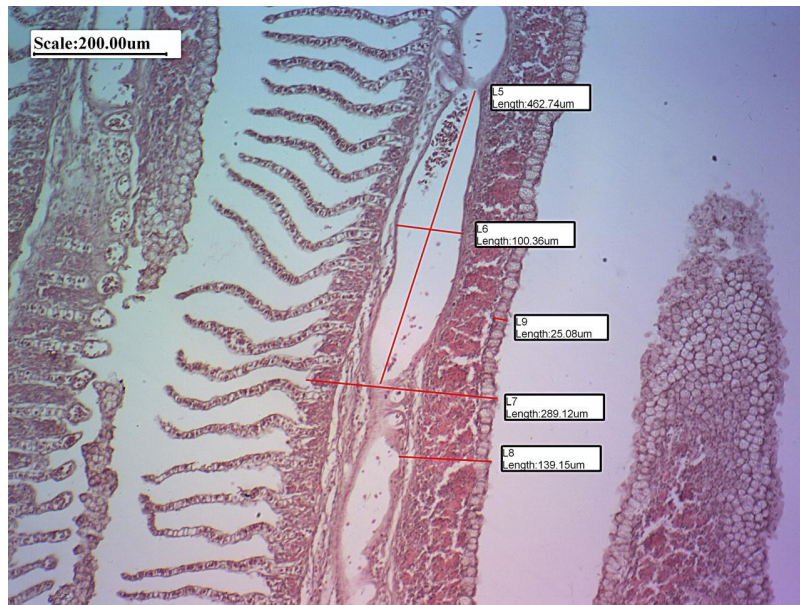


The arrows indicate the location of the parasites and the necrosis caused by them. 1 – myxosporean in gill filaments. Hematoxylin-eosin staining, magnification x4.

The intracellular location of the parasites and the accumulation of mast cells on the apical surface of the affected gills can be seen on histological preparations

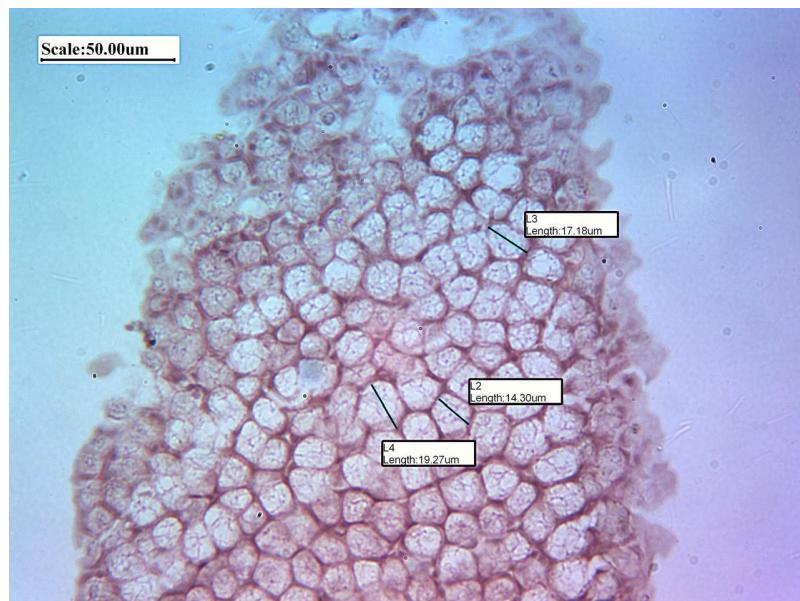
(Figure 3, 4). This stage, in which plasmodium daughter cells are formed in the primary cell is well described in the literature (Molnár & Eszterbauer, 2015).

Figure 3
Destruction of gill fillaments and lamellae.



Hematoxylin-eosin staining, magnification x10.

Figure 4
Microphotograph of cysts containing immature plasmodia of myxosporeans in the gills of young-of-the-year mirror carp.



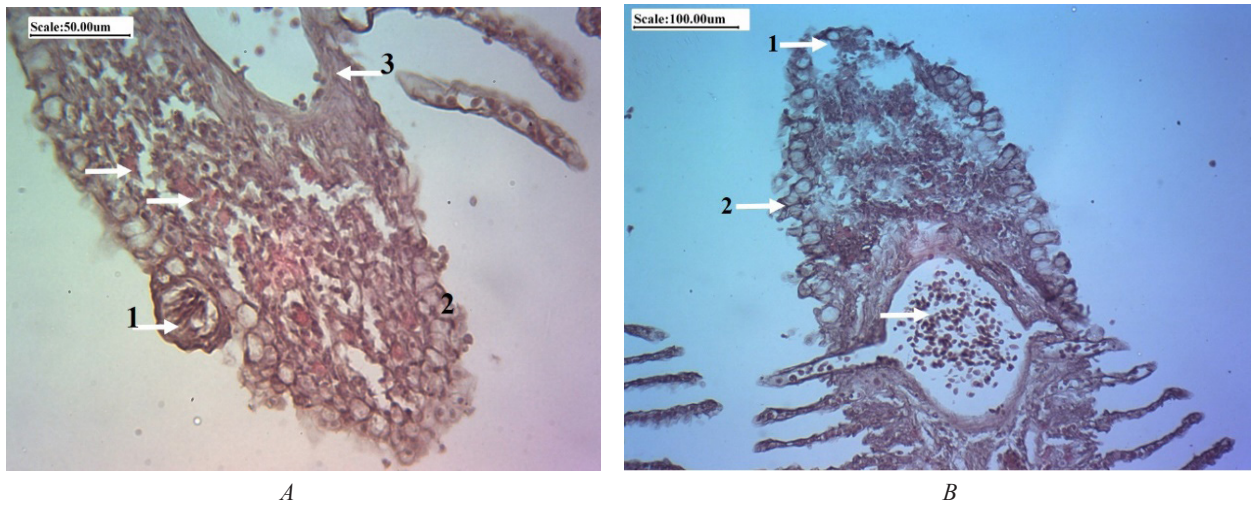
Hematoxylin-eosin staining, magnification x40.

Histological examination of the gills of young-of-the-year mirror carp revealed “diffuse infiltration”, which is manifested by the mixing of small and large parasitic plasmodia with different elements of host cells. A sharp increase in the number

of mast cells in the gills of young-of-the-year mirror carp indicates the presence of parasitic invasion, causing an inflammatory reaction with the production of immune cells in the tissue of the gills (Figure 5).

Figure 5

Microphotographs of the gills of young-of-the-year mirror carp.



A) The arrows indicate mast cells. 1-cyst with spores; 2-cyst with plasmodia; 3- cyst with membrane. Hematoxylin-eosin staining, magnification x40; B) 1 – necrosis; 2- cyst with plasmodia. Hematoxylin-eosin staining, magnification x20.

All identified gill pathologies in the fish studied were caused by plasmodia and myxosporean spores. Thus, the external form of plasmodia depends on the location of the parasite, the reaction of the host organ or tissue to its presence, and the complex interaction between the host and the parasite.

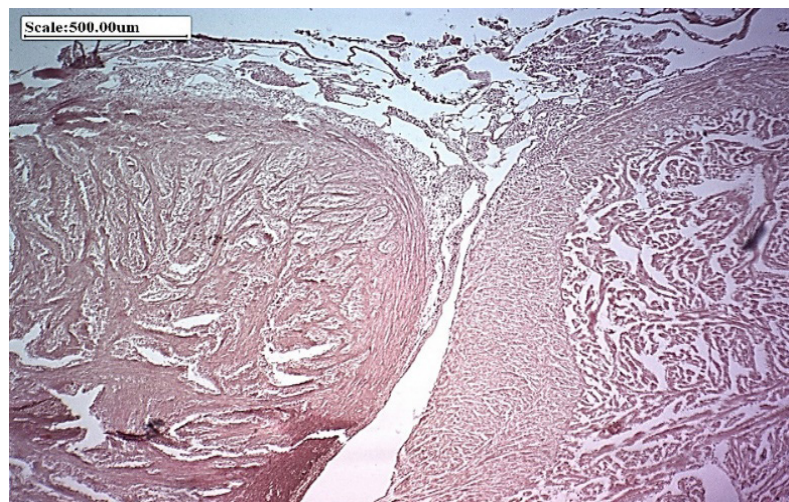
Heart. Histological examination of the cardiac muscle of young-of-the-year mirror carp revealed areas of pathomorphological changes caused by parasitic invasion. Numerous mononuclear and multinuclear

plasmodia were detected in the intramuscular tissue of the heart (Figure 6). Loss of transverse striation in muscle cells and myocyte necrosis were observed.

In the muscle fibers and cardiomyocytes of the heart in young-of-the-year mirror carp, disorganization was observed, caused by mononuclear plasmodial cells of myxosporeans (Figure 7A). Additionally, the development of adipose and connective tissue was detected in the cardiac muscle tissue (Figure 7B).

Figure 6

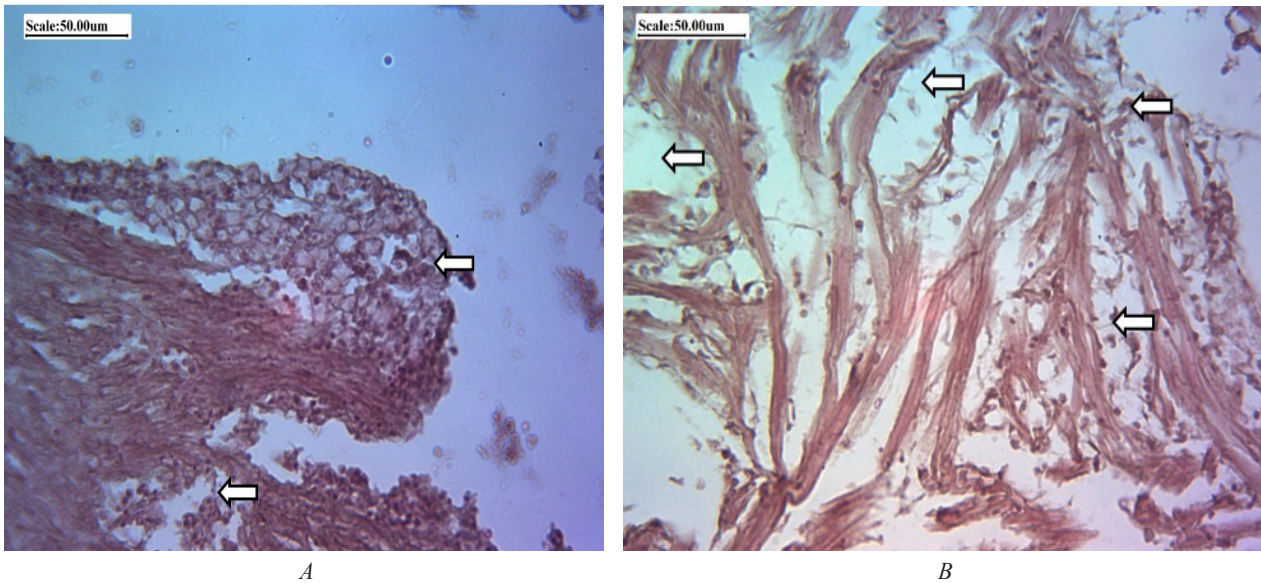
Microphotograph of the heart of a mirror carp.



Hematoxylin-eosin staining, magnification x4.

Figure 7

Microphotograph of the heart of a young-of-the-year mirror carp.



A) The arrows indicate the localization of the parasites in the atrium; B) The arrows indicate different degrees of muscle tissue destruction. Hematoxylin-eosin staining, magnification x40.

Intestine. Necropsy of young-of-the-year mirror carp revealed a thin, fragile intestinal wall with a distended, flaccid intestine filled with yellowish mucous content. In the epithelium of the mucous layer, there were single cysts of various sizes, causing a disruption in food absorption. According to the literature, weakened carp often develop secondary enteritis, which can also lead to death (Wang, 2005).

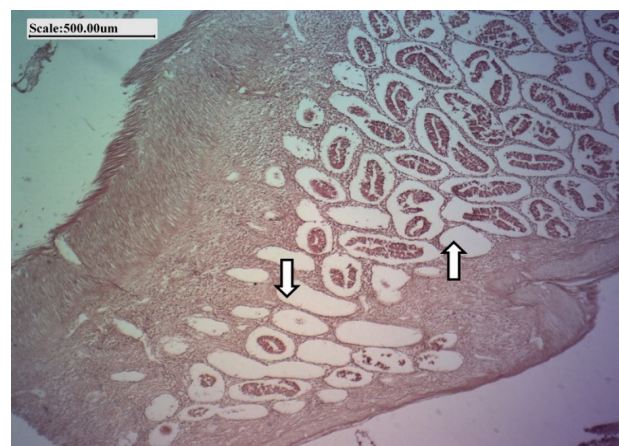The pathomorphological study of the middle section of the intestine revealed structural and functional disorders in the epithelium and submucosa of the intestine of the young-of-the-year mirror carp (Figure 8). The cellular response to plasmodia invasion by manifested by lymphocyte and granulocyte infiltration.

In some areas, degeneration of the microvilli of prismatic enterocytes was observed, along with cell stratification and necrosis; the height of the columnar epithelial cells was significantly reduced, and their boundaries became indistinct. At later stages of development, pressure from the surrounding epi-

thelium caused atrophy and, consequently, loss of integrity of the epithelial layer. (Figure 9A, B).

Figure 8

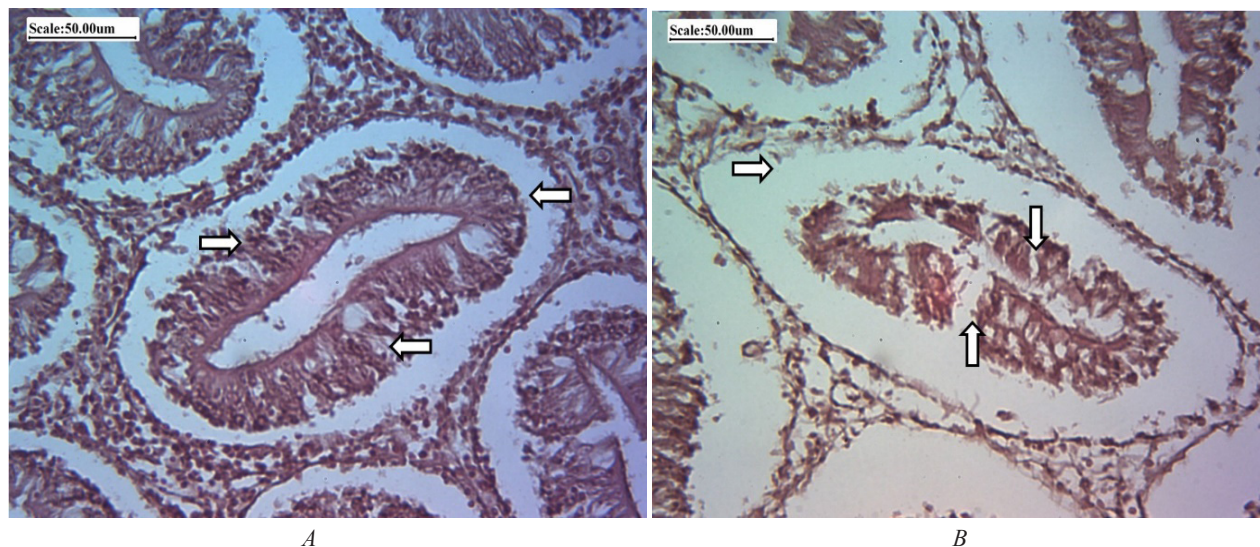
Microphotograph of the intestine of a young-of-the-year mirror carp.



Hematoxylin-eosin staining, magnification x4.

Figure 9

Microphotograph of the intestine of a mirror carp.



A, B – arrows indicate plasmodia and edema located in the epithelium. Hematoxylin-eosin staining, magnification x40.

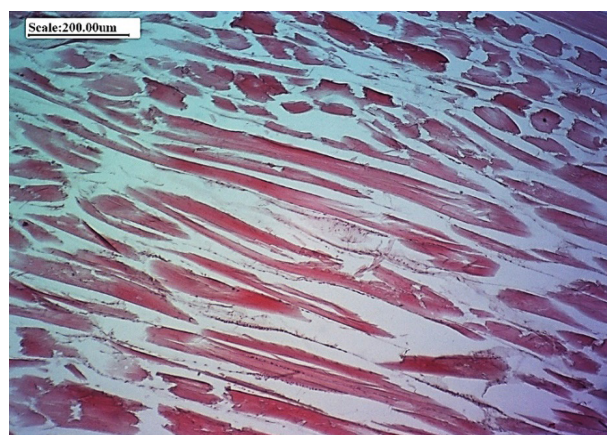
Musculature. The plasmodia stage of mucous spores parasitizes mainly in the trunk and intercostal muscles. The external manifestation of the early stages of parasites is redness caused by inflammation and hemorrhages of different sizes on the skin of fish (Shulman, 1968). The next stages of the life cycle of mucous sporozoans are accompanied by cyst formation, with the development of ulcers, which can heal and cicatrize in the absence of secondary infection (Bauer & Greze, 1948).

Histological analysis of the trunk muscles taken from under the skin ulcers showed destruction of muscle fibers: swelling of the fibers; absence of transverse striations; necrosis of myocytes with the formation of loose connective tissue. Necrosis and dystrophy of muscle fibers were also observed in parts removed from external skin ulcers. Early degenerative and inflammatory changes in fish skeletal muscle include loss of sarcoplasmic integrity, edema, and intense macrophage infiltration, which causes myophagy of the necrotic sarcoplasm (Figure 10).

As recent studies of the developmental cycle of mucous sporozoans have shown, spore formation can occur in the spongy and compact layers of the dermis. Morphological and genetic identification of the *T. kitauei* myxospore was carried out without detection of plasmodia. Scientists explain this discovery as a “habitat transfer” from the intestinal epithelium to the skin (Zhai et al., 2016).

Figure 10

Histological section of the musculature carp mirror at the level of ulcer



Hematoxylin-eosin staining, magnification x10

It has been established that the cause of fish death in myxosporidiosis can be disorders in the digestive tract that cause mechanical intestinal obstruction due to blockage of the intestinal lumen when large tissue plasmodia exit the intestinal mucosa (Rhee, 1994), which contributes to the development of fatal secondary enteritis. Currently, there are no effective measures to protect against diseases caused by myxosporidium (Liu et al., 2016).

Prevention is based on disinfection of pond beds and, as necessary, reduction of the number of alternative hosts (oligochaetes). To more fully and accurately characterize the epizootic situation in aquaculture, it is necessary to conduct ichthyoparasitological studies covering all fish species across different seasons of the year.

Conclusion

It is known that fish blood serves as a sensitive indicator of infectious and invasive diseases by changes in hematological parameters without causing pathological alterations in red blood cells. In the blood of infected young-of-the-year mirror carp, decreased red blood cell counts and hemoglobin levels are observed. An increase in monocyte counts in mirror carp to 11.34% indicates monocytosis associated with an inflammatory process in the gill apparatus. Neutrophils also show a sharp increase compared to the normal values in young-of-the-year mirror carp, reaching 32.68%, indicating phagocytic activity associated with inflammation.

Comparison of white blood cell counts revealed that young-of-the-year mirror carp ($257.6 \times 10^9/L$) exhibit a high degree of invasion by myxosporeans, indicating acute inflammation leading to high mortality rates in infected fish. At low infestation intensities, the disease progresses chronically, and mild

infestations appear harmless to the fish, which is a deceptive impression.

The study showed that myxosporidian infection causes significant hematological and pathological abnormalities in young-of-the-year mirror carp. Affected fish exhibit decreased hemoglobin levels and red blood cell counts, while white blood cell, neutrophil, and monocyte counts increase significantly, reflecting active inflammation and intoxication.

Histological studies have revealed serious destructive changes in the gills, heart, intestines, and skeletal muscles, including necrosis, infiltration, and epithelial damage. Disruption of organ structure leads to impaired respiratory and digestive function, contributing to the high mortality associated with myxosporidiosis.

The lack of effective treatment methods highlights the importance of preventive measures, such as pond bed disinfection, control of oligochaete populations, and regular ichthyoparasitological monitoring. Myxosporeans pose a serious threat to aquaculture by reducing the sustainability and productivity of farmed carp.

Acknowledgments

We thank the Khamitsky fish farm (Shardara, Turkestan Region) for providing the materials for this study.

Author Contributions

Seidaliyeva Nagima Maratbekovna: Conceptualization, Data curation, Formal Analysis, Funding acquisition, Investigation, Methodology, Project administration, Resources, Writing – review & editing; Ibragimova Nailya Akhtamovna: Formal Analysis, Supervision, Validation, Funding acquisition, Writing – review & editing; Saidakhmetova Aidana Kanatkyzy: Data curation, Resources, Visualization, Funding acquisition, Writing, Writing – review & editing; Ussipbek Botagoz Abdykhanovna: Software, Visualization, Funding acquisition, Supervision; Mirzaliyeva Dinara Beisenbekovna: Software, Writing, Funding acquisition, Methodology; Shalgimbayeva Saule Mukhametkaliyevna: Data curation, Investigation, Formal Analysis, Methodology, Project administration, Resources, Supervision, Validation, Writing – review & editing.

References

- Badryzlova, N. S., Fedorov, E. V., & Koishibaeva, S. K. (2014). Osobennosti tovarnogo vyrashchivaniya russkogo osetra v polikul'ture s rastitel'noyadnymi rybami v usloviyakh karpovykh rybovodnykh khozyaystv yuga Kazakhstana [Features of commercial pond cultivation of Russian sturgeon in polyculture with herbivorous fish in carp fish farms of southern Kazakhstan]. *Voprosy rybolovstva*, 15(1), 118–133. (In Russian)
- Bancroft, J. D., & Gamble, M. (2008). *Bancroft's theory and practice of histological techniques* (7th ed.). Elsevier.
- Bauer, O. N., & Greze, V. N. (1948). Parazity ryb ozera Taymyr [Parasites of fishes of Lake Taimyr]. *Izvestiya VNIORKH*, 27, 186–195. (In Russian)
- Bruno, D. W., Alderman, D. J., & Schlotfeldt, H. J. (1997). *What should I do? A practical guide for the marine fish farmer*. European Association of Fish Pathologists.
- Chernycheva, N. B. (2002). Ispol'zovanie gistologicheskogo metoda v ikhtopatologii [Use of the histological method in ichthyopathology]. In *Problemy vosproizvodstva, kormleniya i bor'by s boleznyami ryb pri vyrashchivanii v iskusstvennykh usloviyakh* (pp. 168–170). Karelian Research Center of the Russian Academy of Sciences. (In Russian)
- Davydov, O. N. (2006). Patologiya krovi ryb [Fish blood pathology]. *INKOS*. (In Russian)
- Donets, Z. S., & Shulman, S. S. (1984). Knidosporidii (Cnidosporidia). In O. N. Bauer (Ed.), *Opredelitel' parazitov presnovodnykh ryb SSSR* (Vol. 1, pp. 88–251). Nauka. (In Russian)

- Dugarov, Zh. N., Pronin, N. M., & Sondueva, L. D. (2011). Zavisimost' struktury soobshchestv parazitov plotvy *Rutilus rutilus* ot vozrasta khozyaina [Dependence of parasite community structure of roach on host age]. *Inland Water Biology*, 4(1), 86–97. (In Russian)
- Eiras, J. C., Molnár, K., & Lu, Y. S. (2005). Synopsis of the species of the genus *Myxobolus* Bütschli, 1882 (Myxozoa, Myxosporae, Myxobolidae). *Systematic Parasitology*, 61(1), 1–46. <https://doi.org/10.1007/s11230-004-6343-9>
- Eiras, J. C., Zhang, J., & Molnár, K. (2014). Synopsis of the species of *Myxobolus* Bütschli, 1882 described between 2005 and 2013. *Systematic Parasitology*, 88(1), 11–36. <https://doi.org/10.1007/s11230-014-9484-5>
- Food and Agriculture Organization of the United Nations. (2017). Cultured aquatic species information programme: *Cyprinus carpio*. https://www.fao.org/fishery/en/culturedspecies/Cyprinus_carpio
- Clauss T.W., Dove A.D.M., et al. (2008) Hematologic disorders of fish // *Veterinary Clinics of North America Exotic Animal Practice*. – 11(3). – P. 445-462.
- Golovina, N. A. (2018). Gematologicheskie issledovaniya i ikh ispol'zovanie dlya otsenki zdorov'ya ryb [Hematological studies and their use in fish health assessment]. *Rybovodstvo i akvakul'tura*, (5), 72–79. (In Russian)
- Hallett, S. L., Atkinson, S. D., Erséus, C., & El-Matbouli, M. (2005). Dissemination of triactinomyxons (Myxozoa) via oligochaetes used as live food for aquarium fishes. *Diseases of Aquatic Organisms*, 65(2), 137–152. <https://doi.org/10.3354/dao065137>
- Ivanova, N. T. (1983). Atlas kletok krovi ryb [Atlas of fish blood cells]. Light and Food Industry. Moscow: «Legkaya i pishchevaya promyshlennost», 1983. – 184 p. (In Russian)
- Kent, M. L., Shaw, R. W., & Sanders, J. L. (2014). Microsporidia in fish. In L. M. Weiss & J. J. Becnel (Eds.), *Microsporidia: Pathogens of Opportunity* (1st ed., pp. 493–520). John Wiley & Sons, Inc. <https://doi.org/10.1002/9781118395264.ch20>
- Kent, M. L., Andree, K. B., Bartholomew, J. L., El-Matbouli, M., Desser, S. S., Devlin, R. H., Feist, S. W., Hedrick, R. P., Hoffmann, R. W., Khattra, J., Hallett, S. L., Lester, R. J. G., Longshaw, M., Palenzuela, O., Siddall, M. E., & Xiao, C. (2001). Recent advances in our knowledge of the Myxozoa. *Journal of Eukaryotic Microbiology*, 48(4), 395–413. <https://doi.org/10.1111/j.1550-7408.2001.tb00362>
- Liu, X. H., Batueva, M. D., & Zhao, Y. L. (2016). Morphological and molecular characterisation of *Myxobolus pronini* n. sp. (Myxozoa: Myxobolidae) from gibel carp in Russia and China. *Parasites & Vectors*, 9, Article 562. <https://doi.org/10.1186/s13071-016-1836-3>
- Liu, Y., Lövy, A., Gu, Z., & Fiala, I. (2019). Phylogeny of Myxobolidae and evolution of myxospore appendages. *International Journal for Parasitology*, 49(7), 523–530. <https://doi.org/10.1016/j.ijpara.2019.02.009>
- Lom, J., & Dyková, I. (2006). Myxozoan genera: Definition and notes on taxonomy, life-cycle terminology and pathogenic species. *Folia Parasitologica*, 53(1), 1–36. <https://doi.org/10.14411/fp.2006.001>
- Lom, J., & Dyková, I. (1992). Fine structure of triactinomyxon early stages and sporogony. *Journal of Protozoology*, 39(1), 16–27. <https://doi.org/10.1111/j.1550-7408.1992.tb01279>
- Mineev, A. K. (2011). Nekotorye gistologicheskie patologii pecheni i serdtsa u ryb [Some histological pathologies of fish liver and heart]. *Vestnik Samarskogo nauchnogo tsentra RAN*, 13(1), 203–206. (In Russian)
- Mitenev, V. K. (2000). Parazity karpovykh ryb Kols'kogo Severa [Parasites of Cyprinidae fishes of the Kola North]. Murmansk. (In Russian)
- Moiseenko, T. I. (2009). *Vodnaya ekotoksikologiya* [Aquatic ecotoxicology]. Nauka. (In Russian)
- Moiseenko, T. I. (2000). Morphological restructuring of fish organisms under pollution influence. *Russian Journal of Ecology*, (6), 463–472.
- Molnár, K., & Eszterbauer, E. (2015). Specificity of infection sites in vertebrate hosts. In B. Okamura, A. Gruhl, & J. L. Bartholomew (Eds.), *Myxozoan evolution, ecology and development* (pp. 295–313). Springer.
- Peskova, T. Yu. (2004). *Adaptatsionnye izmeneniya zemnovodnykh v antropogenno zagryaznennoy srede* [Adaptive changes of amphibians in anthropogenically polluted environments] (Doctoral dissertation). Tolyatti. (In Russian)
- Rhee, J. K. (1994). Supplemental knowledge on survival of *Thelohanellus kitauei* spores in vitro. *The Korean Journal of Parasitology*, 32(1), 57–59. <https://doi.org/10.3347/kjp.1994.32.1.57>
- Serpunin, G. G. (2005). *Metody gematologicheskikh issledovaniy ryb* [Methods of hematological studies of fish]. Kaliningrad. (In Russian)
- Serpunin, G. G. (2010). *Gematologicheskie pokazateli adaptatsiy ryb* [Hematological indicators of fish adaptation]. KSTU. (In Russian)
- Shulman, S. S. (1968). Mnogokletochnaya priroda knidosporidii [Multicellular nature of cnidosporidia]. *Parazitologiya*, 11(6), 486–494. (In Russian)
- Wang, Y. P. (2005). Pathogenic mechanism and hematology analysis of *Thelohanellus kitauei*. *Tianjin Fisheries*, (4), 24–27.
- Witeska M., Lugowska K., Kondera E. (2016) Reference values of hematological parameters for juvenile *Cyprinus carpio* // *Bull. Eur. Assoc. Fish Pathol.* – 36(4). – P.169–180.
- Zhai, Y., Gu, Z., Guo, Q., Wu, Z., Wang, H., & Liu, Y. (2016). New pathogenicity type of *Thelohanellus kitauei* infecting carp skin. *Parasitology International*, 65(1), 78–82. <https://doi.org/10.1016/j.parint.2015.10.010>

Information about authors:

Seidalievа Nagima Maratbekovna – PhD student in the Department of Zoology, Histology, and Cytology, Faculty of Biology and Biotechnology, Al-Farabi Kazakh National University (Almaty, Kazakhstan; e-mail: seidalieva_nagima@mail.ru).

Ibragimova Nailya Akhmatovna – Head of the Pharmacology Laboratory of JSC Scientific Center for Anti-Infectious Drugs (Almaty, Kazakhstan; e-mail: nailya.73@mail.ru).

Saidakhmetova Aidana Kanatkyzy – Master of Education; Senior Lecturer, Department of Normal Anatomy named after S.R. Karynbayev of the S. Asfendiyarov Kazakh National Medical University (Almaty, Kazakhstan; e-mail: saidakhmetova.a@kaznmu.kz).

Ussipbek Botagoz Abdykhanovna – PhD, an Acting Associate Professor in the Department of Biophysics, Biomedicine, and Neurosciences, Faculty of Biology and Biotechnology, Al-Farabi Kazakh National University (Almaty, Kazakhstan; e-mail: ussipbek.botagoz@kaznu.kz).

Mirzalieva Dinara Beisenbekovna – Senior Lecturer, Department of Biophysics, Biomedicine and Neuroscience, Faculty of Biology and Biotechnology, Al-Farabi Kazakh National University (Almaty, Kazakhstan; e-mail: dinara-myrzalieva@mail.ru).

Shalgimbayeva Saule Mukhametkaliyevna – candidate of biological sciences, Associate Professor in the Department of Zoology, Histology, and Cytology, Faculty of Biology and Biotechnology, Al-Farabi Kazakh National University (Almaty, Kazakhstan; e-mail: s.saule777@gmail.com).

Авторлар туралы мәлімет:

Сейдалиева Нагима Маратбекқызы – әл-Фараби атындағы Қазақ Ұлттық университеті, Биология және биотехнология факультеті, Зоология, гистология және цитология кафедрасының PhD- докторанты (Алматы, Қазақстан; e-mail: seidalieva_nagima@mail.ru).

Ибрагимова Наилья Ахтамовна – «Инфекцияға қарсы препараттар ғылыми орталығы» АҚ фармакология зертханасының меңгерушісі (Алматы, Қазақстан; e-mail: nailya.73@mail.ru).

Сайдахметова Айдана Қанатқызы – Білім магистрі; С. Асфендияров атындағы Қазақ Ұлттық медициналық университеті, С.Р. Қарынбаев атындағы қалыпты анатомия кафедрасының аға оқытушысы (Алматы, Қазақстан; e-mail: saidakhmetova.a@kaznmu.kz).

Үссіпбек Ботагөз Абдыханқызы – PhD, әл-Фараби атындағы Қазақ Ұлттық университеті, Биология және биотехнология факультеті, Биофизика, биомедицина және нейроғылым кафедрасының доцент міндетін атқарушы (Алматы, Қазақстан; e-mail: ussipbek.botagoz@kaznu.kz).

Мирзалиева Динара Бейсенбековна – әл-Фараби атындағы Қазақ Ұлттық университеті, Биология және биотехнология факультеті, Биофизика, биомедицина және нейроғылым кафедрасының аға оқытушысы (Алматы, Қазақстан; e-mail: dinara-myrzalieva@mail.ru).

Шалгимбаева Сауле Мухаметкалиевна – б.ғ.к., әл-Фараби атындағы Қазақ Ұлттық университеті, Биология және биотехнология факультеті, Зоология, гистология және цитология кафедрасының қауымдастырылған профессоры (Алматы, Қазақстан; e-mail: s.saule777@gmail.com).

Сведения об авторах:

Сейдалиева Нагима Маратбековна – PhD-докторант кафедрасы зоологии, гистологии и цитологии факультета биологии и биотехнологии Казахского национального университета им. аль-Фараби (Алматы, Казахстан, e-mail: seidalieva_nagima@mail.ru).

Ибрагимова Наилья Ахтамовна – заведующая фармакологической лабораторией Научного центра противинфекционных препаратов АО (Алматы, Казахстан, e-mail: nailya.73@mail.ru).

Сайдахметова Айдана Канатовна – магистр, старший преподаватель кафедры нормальной анатомии им. С.Р. Карынбаева Казахского национального медицинского университета им. С. Асфендиярова (Алматы, Казахстан, e-mail: saidakhmetova.a@kaznmu.kz).

Уссіпбек Ботагөз Абдыхановна – PhD, кандидат наук, и. о. доцента кафедры биофизики, биомедицины и нейронаук факультета биологии и биотехнологии Казахского национального университета им. аль-Фараби (Алматы, Казахстан, e-mail: ussipbek.botagoz@kaznu.kz).

Мирзалиева Динара Бейсенбековна – старший преподаватель кафедры биофизики, биомедицины и нейронаук факультета биологии и биотехнологии Казахского национального университета им. аль-Фараби (Алматы, Казахстан, e-mail: dinara-myrzalieva@mail.ru).

Шалгимбаева Сауле Мухаметкалиевна – к. б. н., ассоциированный профессор кафедры зоологии, гистологии и цитологии факультета биологии и биотехнологии Казахского национального университета им. аль-Фараби (Алматы, Казахстан, e-mail: s.saule777@gmail.com).

Received October 25, 2025
Accepted February 20, 2026